



BASIC SCIENCE AND ELBOW

Effects of shoulder position on axillary nerve positions during the split lateral deltoid approach

Sunny Cheung, MD, Michael Fitzpatrick, MD, Thay Q. Lee, PhD*

Orthopaedic Biomechanics Laboratory, VA Long Beach Healthcare System and University of California, Irvine

Background: The axillary nerve may be injured during percutaneous fixation of proximal humerus fractures. This study investigated the kinematic behavior of the superior and inferior borders of the axillary nerve under varying shoulder positions. This information may reduce iatrogenic neurologic injury during fracture reduction and hardware placement.

Methods: The lateral deltoid approach was performed on 7 fresh frozen shoulders. The inferior and superior borders of the axillary nerve were tagged. Screws were placed in the anterior, middle, and posterior acromion as landmarks. Three-dimensional distances of the inferior and superior border of the nerve were measured to the mid-acromion while the shoulder was placed in combinations of forward flexion, vertical abduction, and humeral rotation. The distances were compared by repeated measures ANOVA statistical analysis.

Results: The distance from the mid-acromion to the superior border of the axillary nerve was 66.6 mm (± 5.7), and to the inferior axillary nerve was 75.7 mm (± 5.8) with the shoulder in neutral position. Vertical abduction to 60° significantly moved the superior and inferior borders of the axillary nerve to a distance of 53.9 (± 7.7) and 61.6 mm (± 8.1), respectively ($P < 0.005$). Forward flexion had no significant effect on the position of the axillary nerve ($P > 0.5$). The longest distance from the mid-acromion to the inferior border of the axillary nerve was 86 mm with the arm forward flexed.

Conclusions: The main determinant of axillary nerve position with respect to the acromion is vertical abduction. Axillary nerve position is essentially unaffected by varying degrees of humeral rotation and forward flexion. Vertical glenohumeral abduction to 60° is required to move the nerve significantly closer to the acromion.

Level of Evidence: Basic science anatomic study

© 2009 Journal of Shoulder and Elbow Surgery Board of Trustees.

Keywords: Axillary nerve; proximal humeral fractures; iatrogenic nerve injury; fracture reduction; hardware placement

Most surgeons are familiar with the split lateral deltoid approach to the shoulder for addressing fractures of the proximal humerus and lesions of the rotator cuff. The

dangers of iatrogenic injury to the axillary nerve during this approach is widely recognized.^{12,16} As a result, the anatomy of the axillary nerve within the deltoid has been well studied.^{3-5,8,9} The distance from the nerve to the tip of the acromion has often been cited to be approximately 5 cm.^{4,5,14,16} A cadaveric study found that the nerve is about 6 cm inferior to the top of the humeral head.² Recently, Cetik et al characterized a quadrangular “safe zone”

*Reprint requests: Thay Q Lee, PhD, Orthopaedic Biomechanics Laboratory, VA Long Beach Healthcare System (09/151), 5901 East 7th Street, Long Beach, CA 90822.

E-mail address: tqlee@med.va.gov, tqlee@uci.edu (T.Q. Lee).

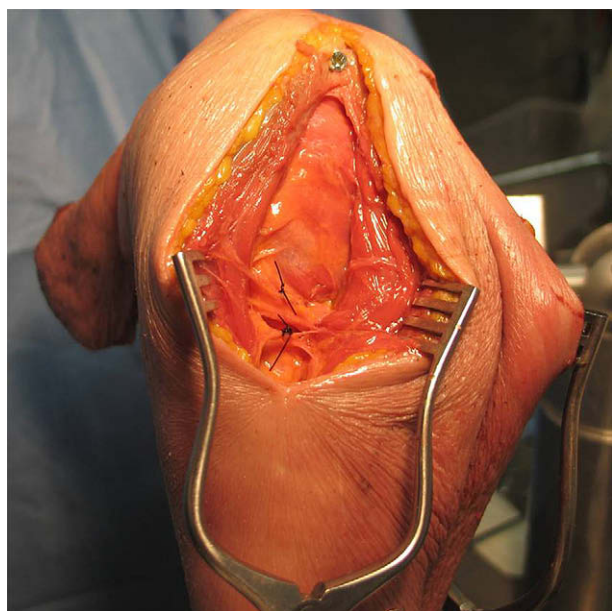


Figure 1 Split deltoid incision with superior and inferior border of the axillary nerve tagged with sutures (left shoulder; screw denotes the mid-acromion).

inferior to the acromion for safe placement of hardware based on the ratio of arm length⁵; quantitatively, they found that the axillary nerve passed inferiorly on average 60.8 mm below the anterior acromial edge and 48.7 mm below the posterior acromial edge.

However, there have only been 2 studies examining the position of the axillary nerve with respect to varying shoulder positions such as vertical abduction, extension, and rotation. Burkhead et al measured the distance of the axillary nerve to the mid-acromion in neutral and 90° vertical abduction, and found it to be 61 mm and 45 mm, respectively.⁴ Bailie et al examined the posterior deltoid splitting approach, and found the distance from the axillary nerve to the posterolateral corner of the acromion to be 65 mm in neutral and decreased to 51 mm in 90° vertical abduction and 46 mm in 30° extension.¹ They also found the distances at 45° internal rotation and 45° external rotation to be 62 and 61 mm, respectively. To date, no study has specifically examined the effects of forward flexion, vertical abduction, and humeral rotation on the proximity of the axillary nerve to the acromion. As it is known that vertical abduction brings the nerve closer to the acromion, it is hypothesized that forward flexion and humeral rotation also may bring the nerve closer or farther away as well.

Finally, the axillary nerve begins to branch in the deltoid and has been shown to have a superior as well as an inferior border.⁸ In a cadaveric study, Kamineni et al reported that the axillary nerve was on average 57 mm distal to the acromion laterally and has a variable width of 6-12 mm as it traverses from lateral to anterior; however, they did not specify the farthest distal extent relative to the acromion.¹⁴ Such information would be helpful when placing screws




Figure 2 Mounted shoulder with scapula in anatomic upright position.

distal to the nerve. Only 1 study by Rowles et al has addressed the safe area inferior to the axillary nerve for percutaneous pinning¹⁸; however, it only suggests that lateral distal pins be placed at a distance that is twice the length of the humeral head. This guideline may not be specific enough for percutaneous plating. Hence, a second objective of this study was to determine the kinematic behavior of the superior and inferior borders of the axillary nerve during a variety of shoulder positions in order to aid in safe placement of orthopedic hardware, especially inferior to the axillary nerve.

Materials and methods

The split lateral deltoid approach to the shoulder was performed on 7 fresh frozen shoulders (2 male, 5 female, mean age 73 [range, 43-91]; 6 left, 1 right). The skin and soft tissues were left as intact as possible to recreate intraoperative conditions. The deltoid was minimally dissected and the axillary nerve was exposed. The superior and inferior borders of the nerve were tagged with a suture each (Figure 1). Small incisions were made over the coracoid as well as the anterior, middle, and posterior acromions; small screws were then placed and used as reproducible bony landmarks to establish digitally the 3-dimensional (3D) orientation of the scapula. None of the specimens had evidence of previous surgery or pathology that significantly altered the anatomy of the lateral shoulder. Three shoulders had been examined previously with a 4-cm longitudinal incision laterally over the acromion to assess the integrity of the rotator cuff for other studies. Another shoulder had both a 7-cm anterior and 5-cm lateral incision to assess the rotator cuff prior. These incisions were repaired in layered fashion and did not affect the course of the axillary nerve, which traveled more distally. A separate posterior incision for the

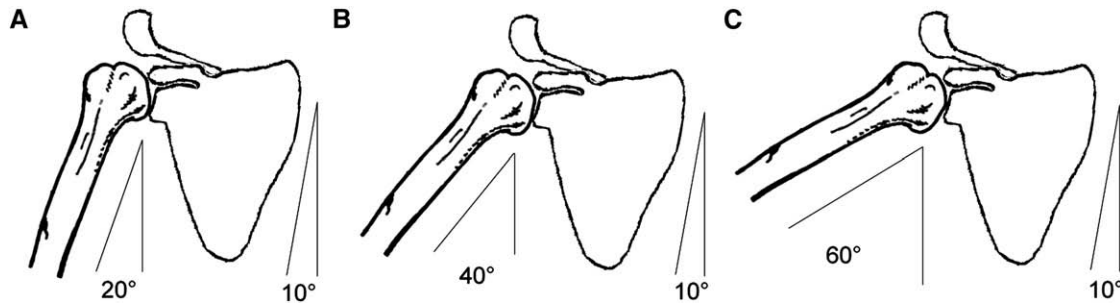


Figure 3 Glenohumeral vertical abduction at 20° (A), 40° (B), and 60° (C). Approximating the 2:1 scapulothoracic rhythm, this corresponds 30°, 60°, and 90° of clinical shoulder abduction. In our study, the scapula is mounted with a 10° tilt. The humerus in these illustrations is at 0° glenohumeral forward flexion (humerus aligned with scapula plane).

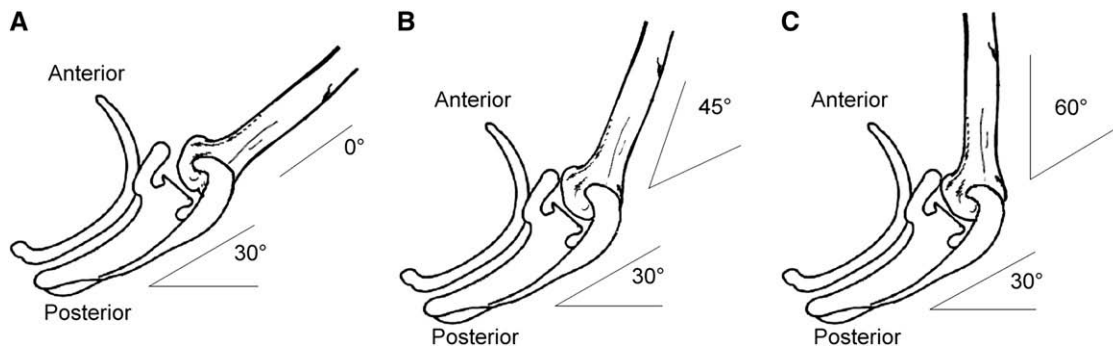


Figure 4 Axial view of thorax illustrating glenohumeral forward flexion at 0° (3d), 45° (3e), and 60° (3f). The humerus in these illustrations is at 60° vertical glenohumeral abduction. The scapula is roughly 30° anteverted with respect to the thoracic cage. Note that 60° glenohumeral forward flexion approximates 90° clinical forward flexion of the shoulder, but only if vertical glenohumeral abduction is involved as well.

shoulder joint was also made for each specimen in a separate concurrent study. This incision was about 10 cm away from the lateral deltoid and did not affect the course of the axillary nerve either.

An aluminum bracket with 3 bolts into the scapula mounted each shoulder in the beach-chair position to a custom built jig with 6° of freedom for the humerus. To simulate its true anatomic position, the body of the scapula was aligned perpendicular to the jig with 20° of anteversion (forward tilt). The jig itself was tilted 10° upwards to approximate the 3° upward tilt of the scapula in the coronal plane plus the variable 5°-15° upward tilt of the glenoid.^{13,15} A fiberglass rod secured by 3 screws in the shaft of the distal humerus was connected to an arc on the jig to control glenohumeral vertical abduction and forward flexion (Figure 2). A single self-retractor was used to expose the skin incision and deltoid just enough to visualize the axillary nerve.

The 3D distance of the tagged structures to the mid-acromial landmark was measured twice with a Microscribe G2LX (Immersion Corporation, San Jose, CA; accurate to 0.30 mm) and the average recorded. The t2 repeated measurements for each parameter had good intraobserver reliability (average difference, 1.0 ± 1.2 mm). Measurements were obtained with the shoulder placed in the following permutation of positions: 1) glenohumeral vertical abduction at 20°, 40°, 60° (Figures 3, A-C); 2) horizontal glenohumeral forward flexion of 0°, 45°, 60° of the humerus with respect to the scapula, defining 0° as the humerus being aligned with the scapula plane (therefore, 60° of glenohumeral forward

flexion would be equivalent clinically to 90° forward flexion of the arm with respect to the entire thorax, taking the natural 30° scapula anteversion relative to the thorax into account [Figures 4, A-C]); and 3) humeral rotation of -45°, -30°, 0°, +30°, +45° (negative numbers are internal rotation and positive are external).

To avoid confusion, we will refer to horizontal glenohumeral forward flexion simply as “forward flexion” for the rest of the paper, which is not the same as “shoulder forward flexion,” as that term implies motion of the shoulder relative to the entire body and usually includes an element of vertical abduction. To set a reference vertical position, previous studies have shown when the humerus is vertical to the ground, the scapula is rotated downward in the sagittal plane such that the glenoid surface is at approximately -(typist: set minus symbol) 5°. ^{10,17} As the scapula was mounted such that the glenoid surface was tilted upward 10°, the true vertical “neutral position” of the humerus in the beach chair position was approximately 15° abduction. This study defined 20° vertical abduction as a reference vertical position, as there would be no effective forward flexion if the arm remained vertically directed towards the ground. The distal end of the fiberglass rod in the humerus was attached to an electronic goniometer to establish humeral rotation. As described elsewhere, neutral humeral rotation was defined by a longitudinal line starting 12 mm posterior to the biceps groove and extending distally down the humeral shaft; at neutral rotation, this line was in alignment with the scapular plane.⁷ Repeated measures ANOVA with post-hoc Tukey testing was used to analyze the data.

Table I Distance of axillary nerve superior border to mid-acromion

		average distance (mm)			Std Deviation (mm)			range (mm)		
		45° Internal Rotation			Glenohumeral Forward Flexion			Glenohumeral Forward Flexion		
		0°	45°	60°	0°	45°	60°	0°	45°	60°
Vertical abduction	20°	66.53	65.32	66.38	5.28	6.18	7.31	57.9–72.2	56.6–74.1	54.1–73.6
	40°	63.11	62.09***	63.25	5.90	6.00	7.81	55.0–71.7	55.5–70.8	53.9–72.5
	60°	53.87*†	55.62*†,d	56.63*†	7.17	7.74	9.41	50.8–65.6	45.9–65.1	44.7–68.1
30° Internal Rotation										
Vertical abduction	20°	66.72	65.37	65.58	5.37	5.74	7.08	59.1–72.6	56.9–73.4	54.9–73.5
	40°	62.44	62.23 ^{a,b}	63.22	6.78	5.89	7.91	52.8–69.8	54.5–70.9	54.9–73.7
	60°	53.76*†	56.07*†	56.94*†	6.77	7.19	9.56	43.2–64.9	47.2–64.9	46.9–70.1
Neutral Rotation										
Vertical abduction	20°	66.59	65.62	65.93	5.71	5.75	6.48	58.4–72.4	55.9–73.6	56.3–74.3
	40°	63.15	63.71	63.91	6.21	6.02	6.70	53.1–70.0	54.4–71.9	56.6–71.3
	60°	53.94*†	55.82*†	56.93*†	7.61	6.21	7.76	42.4–66.6	47.4–64.0	49.4–68.2
30° External Rotation										
Vertical abduction	20°	66.60	66.52	66.39	5.83	5.22	5.04	57.1–71.4	57.6–73.5	59.5–73.6
	40°	63.37	65.65***	64.13	5.90	4.87	6.47	53.9–69.5	60.4–72.5	56.7–70.8
	60°	53.75*†	56.63*†	58.12*†	7.73	6.05	7.36	44.0–67.0	48.1–61.4	51.4–68.3
45° External Rotation										
Vertical abduction	20°	67.11	66.77 ^{‡,§}	67.11	5.69	4.84	4.68	57.9–72.4	58.8–73.2	61.1–73.9
	40°	63.17*	65.92 ^{a,*,*,*,*,*}	64.89	6.91	5.99	5.28	53.2–73.1	55.7–72.9	60.0–70.1
	60°	54.09*†	58.50*†,b,c	58.96*†	7.92	5.76	6.86	43.5–67.0	48.6–64.1	51.7–68.4

* $P < .05$ compared to 20° vertical abduction.

† $P < .05$ compared to 40° vertical abduction.

‡ $P < .05$ compared to 45° internal rotation, 45° forward flexion, 20° vertical abduction.

§ $P < .05$ compared to 30° internal rotation, 45° forward flexion, 20° vertical abduction.

** $P < .05$ compared to 45° internal rotation, 45° forward flexion, 40° vertical abduction.

*** $P < .05$ compared to 30° internal rotation, 45° forward flexion, 40° vertical abduction.

^a $P < .05$ compared to neutral rotation, 45° forward flexion, 40° vertical abduction.

^b $P < .05$ compared to 45° internal rotation, 45° forward flexion, 60° vertical abduction.

^c $P < .05$ compared to neutral rotation, 45° forward flexion, 60° vertical abduction.

^d $P < .05$ compared to 30° internal rotation, 60° forward flexion, 60° vertical abduction.

Results

Glenohumeral vertical abduction

The average distance of the mid-acromion to the axillary nerve superior border was 66.6 mm (SD 5.7; range, 58.4–72.4) in neutral, and decreased to 63.1 mm (SD 6.2, $P = .07$) with 40° vertical abduction and significantly to 53.9 mm (SD 7.7; range, 42.4–66.6, $P < .0003$) with 60° vertical abduction (Table I). The minimum distance of the axillary nerve superior border in any specimen in neutral position was 58.4 mm.

The average distance of the axillary nerve inferior border was 75.7 mm (SD 5.8; range, 67.0–83.8) in neutral,

and decreased significantly to 72.1 mm (SD 7.2; $P = .04$) with 40° vertical abduction and to 61.6 mm (SD 8.1; range, 50.7–76.9, $P < .0002$) with 60° vertical abduction (Table II). The maximum distance of the axillary nerve inferior border in any specimen in neutral position was 83.8 mm.

For both axillary nerve superior and inferior borders, vertical abduction to 60° significantly brought them closer to the mid-acromion for all conditions of humeral rotation and forward flexion ($P < .005$; Tables I and II). For the axillary nerve superior border, vertical abduction to 40° did not significantly bring it closer except under 45° external rotation and 0° forward flexion ($P < .01$). For the axillary nerve inferior border, vertical abduction to 40° significantly

Table II Distance of axillary nerve inferior border to mid-acromion

		average distance (mm)			Std Deviation (mm)			range (mm)		
		Glenohumeral	Forward Flexion		Glenohumeral	Forward Flexion		Glenohumeral	Forward Flexion	
45° Internal Rotation		0°	45°	60°	0°	45°	60°	0°	45°	60°
Vertical abduction	20°	75.92	74.91	76.55	4.99	5.77	7.79	69.9–83.47	68.2–80.9	66.5–86.0
	40°	72.49	70.73	71.86	7.06	6.35	9.54	64.1–84.2	64.9–80.2	60.7–84.1
	60°	61.77 ^{*,†}	63.10 ^{*,†}	65.18 ^{*,†}	7.30	8.41	11.10	54.4–76.0	52.2–73.5	54.8–80.6
30° Internal Rotation		0°	45°	60°	0°	45°	60°	0°	45°	60°
Vertical abduction	20°	75.70	74.72	75.73	5.42	5.38	6.83	68.9–83.0	68.0–80.2	66.1–83.9
	40°	71.82	71.04	71.62	7.62	5.54	8.52	62.1–84.2	65.3–78.1	61.5–80.3
	60°	61.49 ^{*,†}	64.05 ^{*,†}	64.69 ^{*,†}	7.86	9.09	10.37	50.7–76.0	52.6–74.4	53.8–78.4
Neutral Rotation		0°	45°	60°	0°	45°	60°	0°	45°	60°
Vertical abduction	20°	75.72	75.05	75.87	5.75	5.09	6.35	67.0–83.8	67.6–80.8	65.7–83.7
	40°	72.07 [*]	71.96	72.75	7.18	4.93	6.74	62.1–84.2	65.3–78.1	61.5–80.3
	60°	61.61 ^{*,†}	63.54 ^{*,†}	65.20 ^{*,†}	8.14	7.06	9.74	50.7–76.9	53.7–70.9	54.2–77.6
30° External Rotation		0°	45°	60°	0°	45°	60°	0°	45°	60°
Vertical abduction	20°	75.85	75.55	75.91	5.71	5.00	5.59	67.5–83.9	67.6–81.1	67.5–82.6
	40°	72.13 [*]	73.83 ^{‡,§}	73.27	6.23	4.59	6.73	63.1–82.7	68.6–79.0	63.2–81.4
	60°	61.27 ^{*,†}	63.93 ^{*,†}	66.36 ^{*,†}	8.21	6.62	8.72	49.6–76.0	55.1–70.8	55.5–77.5
45° External Rotation		0°	45°	60°	0°	45°	60°	0°	45°	60°
Vertical abduction	20°	76.26	76.19	76.94	5.50	4.67	5.46	68.1–84.4	69.4–82.0	69.2–83.3
	40°	71.72 [*]	74.22 ^{‡,§}	73.69	6.44	6.06	6.26	63.1–82.8	64.2–80.7	64.4–80.4
	60°	61.67 ^{*,†}	65.19 ^{*,†}	67.28 ^{*,†,d}	7.61	5.62	8.26	52.0–75.5	56.9–72.1	57.5–77.9

* $P < .05$ compared to 20° vertical abduction.

† $P < .05$ compared to 40° vertical abduction.

‡ $P < .05$ compared to 45° internal rotation, 45° forward flexion, 40° vertical abduction.

§ $P < .05$ compared to 30° internal rotation, 45° forward flexion, 40° vertical abduction.

** $P < .05$ compared to 45° internal rotation, 45° forward flexion, 20° vertical abduction.

*** $P < .05$ compared to 30° internal rotation, 45° forward flexion, 20° vertical abduction.

^a $P < .05$ compared to neutral rotation, 45° forward flexion, 40° vertical abduction.

^b $P < .05$ compared to 45° internal rotation, 45° forward flexion, 60° vertical abduction.

^c $P < .05$ compared to neutral rotation, 45° forward flexion, 60° vertical abduction.

^d $P < .05$ compared to 30° internal rotation, 60° forward flexion, 60° vertical abduction.

moved the nerve closer under the following conditions only: 0° forward flexion with 0°, 30°, and 45° external rotation ($P < .04$).

Horizontal glenohumeral forward flexion

Forward flexion did not alter significantly the position of the nerve ($P > .05$) for any condition (Tables I and II). In fact, there was much variation; in 4 shoulders the nerve moved further, but in 3 shoulders the nerve actually moved closer. However, combined with increasing vertical abduction, there was a trend to bring both the superior and inferior border of the axillary nerve farther away from the acromion. At 60° vertical abduction and neutral rotation, the act of forward flexion from 0° (humerus aligned with the scapular plane) to

60° brought the average distance of the superior border of the nerve to the mid-acromion from 53.9 mm (SD 7.7) to 56.9 mm (SD 7.8); a difference of 3 mm.

The maximum distance of the axillary nerve inferior border in any specimen and shoulder position was found to be 86.0 mm under 60° forward flexion, neutral vertical abduction, and 45° internal rotation.

Humeral rotation

For the axillary nerve superior border, external rotation produced a small but significant shift away from the acromion only under the following conditions of 45° forward flexion (Table I): 1) When at neutral vertical abduction, the act of humeral rotation to 45° external rotation from both

30° and 45° internal rotation moved the nerve farther on average 1.4 mm ($P = .03$) for both conditions. 2) When at 40° vertical abduction, the act of humeral rotation to 45° external rotation from 45°, 30°, and 0° internal rotation moved the nerve farther on average 3.8, 3.7, and 2.2 mm, respectively ($P < .04$). The act of humeral rotation to 30° external rotation from 45° and 30° internal rotation moved the nerve farther on average 3.6 and 3.4 mm, respectively ($P < .0008$). 3) When at 60° vertical abduction, the act of humeral rotation to 45° external rotation from 45° internal rotation and 0° rotation moved the nerve farther by 2.9 and 2.7 mm, respectively ($P < .03$).

For the axillary nerve inferior border, external rotation produced a small but significant shift away from the acromion only for the following conditions (Table II): 1) At 45° forward flexion, 40° vertical abduction, the act of humeral rotation to 45° external rotation from 45° and 30° internal rotation moved the nerve farther on average 3.5 and 3.2 mm, respectively ($P < .005$); the act of humeral rotation to 30° external rotation from 45° and 30° internal rotation moved the nerve farther on average 3.1 and 2.8 mm, respectively ($P < .02$). 2) At 60° forward flexion, 60° vertical abduction, the act of humeral rotation to 45° external rotation from 30° internal rotation moved the nerve farther on average 2.6 mm ($P < .04$).

Acromial width and distance

There was no correlation between acromial width and the distances of the axillary nerve superior and inferior borders to the acromion ($R^2 = .006$, $P = .87$, $R^2 = .069$, $P = .57$, respectively).

Discussion

There continues to be some disagreement regarding the position of the axillary nerve during the split lateral deltoid approach. According to many authors, the safe zone for splitting the deltoid superior to the axillary nerve varies from 38 mm⁶ to 40 mm¹¹ or 52 mm.⁵ Cetik et al suggested using a ratio of arm length to predict the position of the axillary nerve, with a ratio of 0.20 anteriorly and 0.16 posteriorly.⁵ Burkhead et al found that the axillary nerve in women was significantly closer to the acromion by 10 mm in his dissections.⁴ Given the established variable location of the nerve and that previous studies have already determined that gender and arm length affect the distance of the axillary nerve with respect to the acromion, this study did not attempt to quantify the exact position of the nerve. Rather, the goal of this study was to focus on the kinematics of the axillary nerve with varying shoulder positions. Still, it should be noted that the location of the axillary nerve in our study is consistent with previously published data. The minimum distance of the nerve to the acromion was

observed to be 58.4 mm in the neutral position (0° rotation, 20° vertical abduction, 0° forward flexion). Despite remaining in a vertically neutral position, however, the absolute minimum distance decreased to 54.0 mm under 45° internal rotation with 60° glenohumeral forward flexion (approximately 90° shoulder forward flexion, taking the 30° anteversion of the scapula relative to the thoracic cage into account). To be safe, we recommend splitting the deltoid no more than 50 mm distal to the mid-acromion in any given vertically neutral position in order to avoid injury to the axillary nerve, which is in agreement with published data.

Other studies have demonstrated that vertical abduction can bring the axillary nerve closer to the acromion by 13 to 14 mm, but were not specific on the exact position of the humerus relative to the glenoid.^{1,4} To our knowledge, there have been no studies examining the effect of varying combinations of vertical abduction, forward flexion, and humeral rotation on the position of the axillary nerve. Regarding the safe zone superior to the axillary nerve, our data show that glenohumeral vertical abduction of 60° affects the axillary nerve significantly, bringing it closer by 12.7 mm; this finding is consistent with previous studies.^{1,4} Interestingly, vertical abduction to 40° was not enough to cause significant change, except in 1 condition of external rotation. This may be explained by the fact that the nerve is already positioned further away from the acromion at 45° external rotation than compared to neutral rotation, and this slightly farther distance is enough magnitude to cause a significant difference moving from 20° to 40° vertical abduction. In general, though, given the overall 2:1 glenohumeral to scapulothoracic motion during vertical abduction, this implies that approximately 90° shoulder vertical abduction brings the nerve significantly closer, but not 60° shoulder vertical abduction. Still, the largest distances between the nerve and the acromion were consistently at neutral vertical abduction; therefore, we recommend keeping the shoulder vertically neutral whenever possible to decrease the risk of injury to the nerve.

Horizontal forward flexion increased the distance of the axillary nerve to the acromion, but this trend was not significant. It seems that it is really the vertical abduction component of the forward flexion that tends to bring the nerve farther away. For example, even a large forward flexion (to 60°) by itself with only a low magnitude of vertical abduction (arm pointing relatively straight down) is clinically similar to the shoulder in neutral position. In fact, while in vertically neutral position, the closest distance of the nerve to the acromion (54.1 mm) was found with the shoulder in 60° forward flexion. Thus the data from this study does not demonstrate a consistent trend with regards to axillary nerve position and forward flexion by itself, but rather it is vertical abduction combined with forward flexion that seems to bring the nerve farther away.

In most positions, humeral rotation did not affect the axillary nerve position substantially. While under limited circumstances, external rotation did move the nerve farther;

it only occurred under 45° forward flexion, and the maximum significant change was only 3.8 mm on average. This is likely explained by the fact that at 45° forward flexion, the act of external rotation will rotate the suture being measured (along the axillary nerve) inferiorly, and hence farther from the acromion. Conversely, internal rotation will rotate the suture superiorly up towards the acromion; however, we believe this small effect may not necessarily reflect the true closest distance of the nerve to the acromion. Rotating the humerus moves the tagged suture along the length of the nerve; if we approximate the axillary nerve as a straight line, then the distance being measured (from the suture to acromion) would be a diagonal distance from the line (axillary nerve) to a point (mid-acromion) and not the perpendicular closest distance from that line to the point (Figure 5). To more clearly determine the effect of humeral rotation in the future, it may be advantageous to measure the closest distance of the mid-acromion to the axillary nerve instead of a suture attached to the nerve; however, sutures were used in this study in order to increase reproducibility.

Regarding safe incisions inferior to the axillary nerve, there is no literature specifically for percutaneous plating. Rowles et al studied percutaneous pinning of the proximal humerus in cadaveric shoulders and recommended the distal lateral pins be at least twice the distance distally from the top of the humeral head to the inferior most margin of the head.¹⁸ Our data show that varying shoulder position has essentially the same effect on the axillary nerve inferior border as on the superior border. The maximum distance of the axillary nerve to the acromion was 83.8 mm in the neutral position; but when all positions are examined, the maximum distance was 86 mm at 60° forward flexion. However, we caution that this is a biomechanics study, and that an absolute safe distance for splitting the deltoid distal to the axillary nerve may need to be corroborated with a larger scale anatomic study (which can be the subject of future investigation). Still, given our findings, we recommend a starting point to split the deltoid at least 9 cm distal to the acromion (when the arm is in neutral vertical abduction) to avoid injury to the axillary nerve for safe placement of hardware inferior to the nerve. Because vertical abduction decreases the maximum distance to the inferior border of the axillary nerve (61.6 ± 8.1 mm; range, 50.7-76.9), vertical abduction may aid the surgeon in moving the axillary nerve superiorly, essentially increasing the inferior safe zone for percutaneous fixation.

Finally, the data also shows that there is no correlation between acromial width and the distance of the axillary nerve to the acromion. This result is consistent with the findings from other authors.¹⁹ Other authors have determined that distance from the acromion to the axillary nerve does correlate with overall humeral length.⁵ Though we did not include humeral length measurements in our study design, we felt this correlation has already been well established and is an important factor in surgical decision-making.

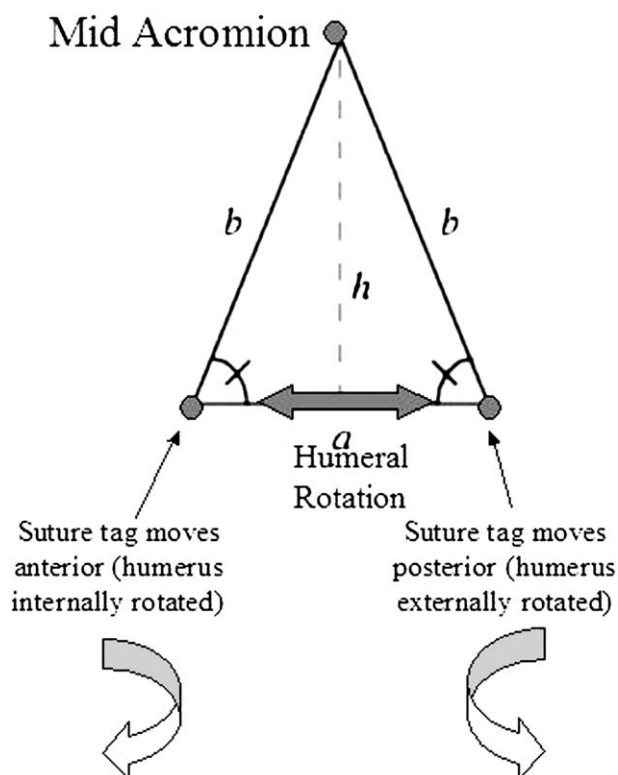


Figure 5 Schematic view of a left acromion and axillary nerve when viewed laterally. The distance of the tagged suture (b) to the acromion may not always reflect the shortest distance of the axillary nerve (h). (a , axillary nerve.)

One limitation of the study is that a fracture of the proximal humerus would likely alter the anatomic position of most structures in the upper arm, including the axillary nerve. This model did not simulate an actual fracture of the proximal humerus, so it should be noted that tissue disruption and alterations in anatomic measurement should be taken into account during the actual surgical procedure. It is beyond the scope of this study to recreate the infinite possibilities of fracture patterns that can potentially occur and map the nerve at the same time. Rather, this serves as a guide for surgeons while they are manipulating or reducing the shoulder. The data obtained from this study can only be accurately used in situations where the proximal humerus fracture is minimally displaced or all of the structures are reduced anatomicly. We acknowledge that the added variables of displacement, angulation, and rotation (which occur when the proximal humerus is fractured) are important variables that will necessitate further studies.

Another limitation is that the study design required that the neurovascular structures be dissected and tagged. Additionally, the specimens were used in a concurrent study which tracked the neurovascular structures during a minimally invasive posterior approach to the shoulder. The incisions required for this study were repaired in a layered fashion and did not affect the course of the axillary nerve. The dissections

were done as minimally as possible in order to avoid distorting the natural anatomy of the structures; however, in order to adequately visualize and measure the structures in a consistent manner, sometimes the structures had to be freed from the connective tissue and retractors placed in the deltoid. This alters the soft tissue anatomy to a small degree but is unavoidable in a cadaveric study. The only way to overcome the problem of dissection causing distortions in measurement would be *in situ* MRI studies where no dissection would be required. Anatomic studies with MRI also have their own inherent weaknesses though, and may be less applicable in a clinical setting where dissection and placement of retractors is required for open treatment internal fixation of proximal humerus fractures anyway.

This study did not quantify intraobserver variability; however, as the objective of this study was to track the position of the nerve at different shoulder positions, markers were placed along the nerve for digitization. A single user was used for marking and digitizing the nerve to increase reproducibility of the marking and digitizing process. Because the markers are digitized, there is no user dependence on the point that is digitized and the variance in digitization would be the repeatability of the Microscribe itself. The interobserver variability was calculated to be an average of 1.0 ± 1.2 mm across all measurements.

Finally, we believe 7 specimens provided adequate power to demonstrate clinical differences in distances due to shoulder positioning. Because the main goal of this kinematic study was to determine the effects of axillary nerve position relative to shoulder position, we feel the number of specimens is sufficient to achieve statistical significance with rigorous repeated measures ANOVA testing. While increasing the number of specimens might increase the ability to detect smaller significant differences, we do not believe it would have altered our conclusions clinically.

Conclusion

In conclusion, vertical abduction has the greatest effect on axillary nerve position. Conversely, horizontal glenohumeral forward flexion and humeral rotation have little effect on axillary nerve position. We determine a safe zone in any vertically neutral shoulder position for hardware placement up to 5 cm distal from the mid-acromion, then a danger area from 5 to 9 cm; distal to 9 cm, the deltoid may be safely split again with minimal risk of injuring the axillary nerve. The surgeon must be aware that the radial nerve crosses the lateral aspect of the proximal arm, inferior to the inferior border of the axillary nerve, and as such must be considered in any percutaneous approach to the lateral humerus. Variations may occur, particularly in arms that are above or below average in size; therefore, the surgeon must always use extreme care during dissections even within these safe zones.

Acknowledgment

The authors would like to thank Michelle McGarry and Joey Pirolo for their assistance in preparing this manuscript.

Disclaimer

Supported in part by the VA Rehab R&D and Medical Research and the John C. Griswold Foundation.

References

- Bailie DS, Moseley B, Lowe WR. Surgical anatomy of the posterior shoulder: effects of arm position and anterior-inferior capsular shift. *J Shoulder Elbow Surg* 1999;8:307-13.
- Bono CM, Grossman MG, Hochwald N, et al. Radial and axillary nerves. Anatomic considerations for humeral fixation. *Clin Orthop Relat Res* 2000;259-64.
- Bryan WJ, Schauder K, Tullos HS. The axillary nerve and its relationship to common sports medicine shoulder procedures. *Am J Sports Med* 1986;14:113-6.
- Burkhead WZJ, Scheinberg RR, Box G. Surgical anatomy of the axillary nerve. *J Shoulder Elbow Surg* 1992;1:31-6.
- Cetik O, Uslu M, Acar HI, et al. Is there a safe area for the axillary nerve in the deltoid muscle? A cadaveric study. *J Bone Joint Surg Am* 2006;88:2395-9.
- Crenshaw AHJ. *Campbell's Operative Orthopaedics*, Canale ST, editor. St. Louis, MO: Mosby, 2003.
- Doyle AJ, Burks RT. Comparison of humeral head retroversion with the humeral axis/biceps groove relationship: a study in live subjects and cadavers. *J Shoulder Elbow Surg* 1998;7:453-7.
- Duparc F, Bocquet G, Simonet J, et al. Anatomical basis of the variable aspects of injuries of the axillary nerve (excluding the terminal branches in the deltoid muscle). *Surg Radiol Anat* 1997;19:127-32.
- Duval MJ, Parker AW, Drez D Jr, et al. The anterior humeral circumflex vessels and the axillary nerve. An anatomic study. *Orthop Rev* 1993;22:1023-6.
- Freedman L, Munro RR. Abduction of the arm in the scapular plane: scapular and glenohumeral movements. A roentgenographic study. *J Bone Joint Surg Am* 1966;48:1503-10.
- Green A. Skeletal trauma: Basic science, management, and reconstruction. In: Browner BDJ, Jesse B, Levine AM, Trafton PG, editors. Amsterdam: Elsevier Inc., 2003.
- Hoppenfeld S, deBoer P. *Surgical exposures, Orthopaedics: The anatomic approach*. Philadelphia, PA: Lippincott, Williams and Wilkins, 2003. p. 41-60.
- Itoi E, Morrey BF, An K-N. Biomechanics of the shoulder. In: Rockwood CA Jr, Matsen F, editors. *The shoulder*. Philadelphia, PA: Saunders, 2004. p. 233.
- Kamineni S, Ankem H, Sanghavi S. Anatomical considerations for percutaneous proximal humeral fracture fixation. *Injury* 2004;35:1133-6.
- O'Brien S, Fealy S, Drakos M, et al. Developmental and gross anatomy of the shoulder. In: Rockwood CA Jr, Matsen F, editors. *The shoulder*. Philadelphia, PA: Saunders, 2004. p. 15.
- Perlmutter GS. Axillary nerve injury. *Clin Orthop Relat Res* 1999;28-36.
- Poppen NK, Walker PS. Normal and abnormal motion of the shoulder. *J Bone Joint Surg Am* 1976;58:195-201.
- Rowles DJ, McGrory JE. Percutaneous pinning of the proximal part of the humerus. An anatomic study. *J Bone Joint Surg Am* 2001;83-A:1695-9.
- Vathana P, Chiarapattanakom P, Ratanalaka R, et al. The relationship of the axillary nerve and the acromion. *J Med Assoc Thai* 1998;81:953-7.